

Eruption and shedding of the teeth

Overview 77

Preeruptive phase 77

Prefunctional eruptive phase 78

- Changes in tissues 80
 - Overlying the teeth 80
 - Surrounding the teeth 83
 - Underlying the teeth 84

Functional eruptive phase 86

Possible causes of tooth eruption 87

Sequence and chronology of tooth eruption 87

Shedding of primary teeth 88

Comparisons of the primary and permanent dentitions 89

- Tooth number and size 89
- Roots 89
- Tooth structure 90
- Pulp shape and size 90
- Arch shape 90
- Root resorption and pulp degeneration 90

Self-evaluation questions 91

Consider the patient discussion 91

Suggested reading 91

Key Terms—cont'd

Intracellular phase	Preeruptive phase
Intraoral occlusal/incisal movement	Prefunctional eruptive phase
Mixed dentition period	Root formation
Movement	Ruffled border
Osteoblasts	Shedding
Osteoclasts	Tissues: overlying, surrounding, underlying
Penetration	

OVERVIEW

Tooth eruption is the process by which developing teeth emerge through the soft tissue of the jaws and the overlying mucosa to enter the oral cavity, contact the teeth of the opposing arch, and function in mastication. The movements related to tooth eruption begin during crown formation and require adjustments relative to the forming bony crypt. This is the **preeruptive phase**. Tooth eruption is also involved in the initiation of root development and continues until the tooth's emergence into the oral cavity, which is the **prefunctional eruptive phase**. The teeth continue to erupt until they reach incisal or occlusal contact. Then, they undergo functional eruptive movements, which include compensation for jaw growth and occlusal wear of the enamel. This stage is the **functional eruptive phase**. Eruption is actually a continuous process that ends only with the loss of the tooth. Each dentition, primary and permanent, has various problems during eruption and in the sequencing of eruption in the oral cavity. Teeth differ extensively in their eruptive schedules as well. This chapter describes these events. Finally, the process of tooth shedding or exfoliation of the primary dentition is discussed (**Boxes 6-1 and 6-2**). Primary tooth loss results from three fundamental causes: root resorption, bone resorption, and size of crown too small to withstand mastication.

Learning Objectives

- Describe the three phases of tooth eruption: preeruption, prefunctional, and functional.
- Describe the initial growth of the tooth and the compensational changes that occur in the surrounding overlying and underlying tissues.

Key Terms

Diphyodont	Functional eruptive phase
Eruption pathway	Gubernaculum dentis or gubernacular cord
Extracellular phase	
Fibroblast	

PREERUPTIVE PHASE

The preeruptive phase includes all movements of primary and permanent tooth crowns from the time of their early initiation and formation to the time of crown completion. Therefore this phase is finished with early initiation of root formation. The developing crowns move constantly in the jaws during the

Box 6-1 Theories of Tooth Eruption

1. Root growth
2. Proliferation of pulp tissue
3. Increased vascularity of the pulp
4. The gubernaculum dentis
5. Development of the “hammock ligament”
6. Development of apical bone (boney ladder)
7. Occurrence of an eruptive pathway
8. Organization and increased vascularity of the periodontal ligament

Box 6-2 Clinical Areas Where Root Resorption Is Important

1. Normal shedding of deciduous teeth
2. Orthodontic tooth movement
3. Transplantation and implantation
4. Idiopathic resorption (internal and external)

preeruptive phase. They respond to positional changes of the neighboring crowns and to changes in the mandible and maxilla as the face develops outward, forward, and downward away from the brain in its maturing growth path. During the lengthening of the jaws, primary and permanent teeth make mesial and distal movements. Eventually the permanent tooth crowns move within the jaws, adjusting their position to the resorptive roots of the primary dentition and the remodeling alveolar processes, especially during the mixed dentition period from 8 to 12 years of age.

Early in the preeruptive period, the permanent anterior teeth begin developing lingual to the incisal level of the primary teeth (Figs. 6-1 and 6-2). Later, however, as the primary teeth erupt, the permanent successors are positioned lingual to the apical third of their roots. The permanent premolars shift from a location near the occlusal area of the primary molars to a location enclosed within the roots of the primary molars (see Fig. 6-2). This change in relative position is the result of the eruption of the primary teeth and an increase in height of the supporting structures. On the other hand, the permanent molars, which have no primary predecessors, develop without this type of relationship (Fig. 6-3). Maxillary molars develop within the tuberosities of the maxilla with their occlusal

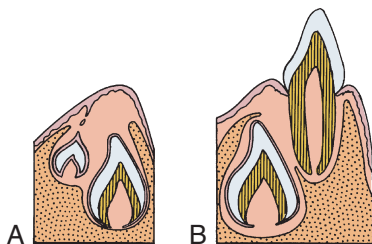


Fig. 6.1 Relative position of primary and permanent incisor teeth. A, Preeruptive period. B, Prefunctional eruptive period.

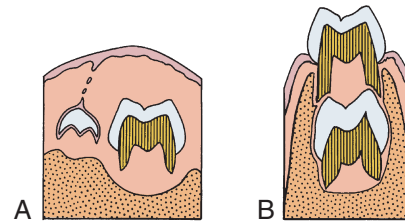


Fig. 6.2 Relative position of primary and permanent molar teeth. A, Preeruptive period. B, Prefunctional eruptive period.

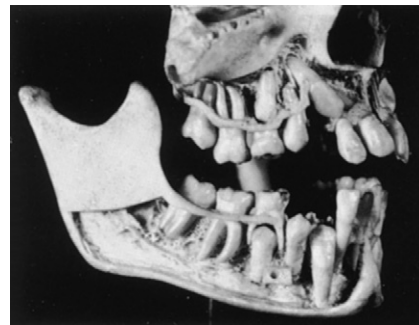

Fig. 6.3 Human jaws at 8 to 9 years of age, during the mixed dentition period. Permanent teeth are replacing primary teeth, and positions of each are shown. The permanent mandibular molar has not emerged from the coronoid process.

surfaces slanted distally. Mandibular molars develop in the mandibular rami with their occlusal surfaces slanting mesially (see Fig. 6-3). This slant is the result of the angle of eruption as the molars arise from the curvature of the condyle of the posterior mandible. All movements in the preeruptive phase occur within the crypts of the developing and growing crown before root formation begins.

PREFUNCTIONAL ERUPTIVE PHASE

The prefunctional eruptive phase starts with the initiation of root formation and ends when the teeth reach occlusal contact. Four major events occur during this phase:

1. **Root formation** requires space for the elongation of the roots. The first step in root formation is proliferation of the epithelial root sheath, which in time causes initiation of root dentin and formation of the pulp tissues of the forming root. Root formation also causes an increase in the fibrous tissue of the surrounding dental follicle (Fig. 6-4).
2. **Movement** occurs incisally or occlusally through the bony crypt of the jaws to reach the oral mucosa. The movement is the result of a need for space in which the enlarging roots can form. The reduced enamel epithelium next contacts and fuses with the oral epithelium (Fig. 6-5). Both of these epithelial layers proliferate toward each other, their cells intermingle, and fusion occurs. A reduced epithelial layer overlying the erupting crown arises from the reduced enamel epithelium (Fig. 6-6).

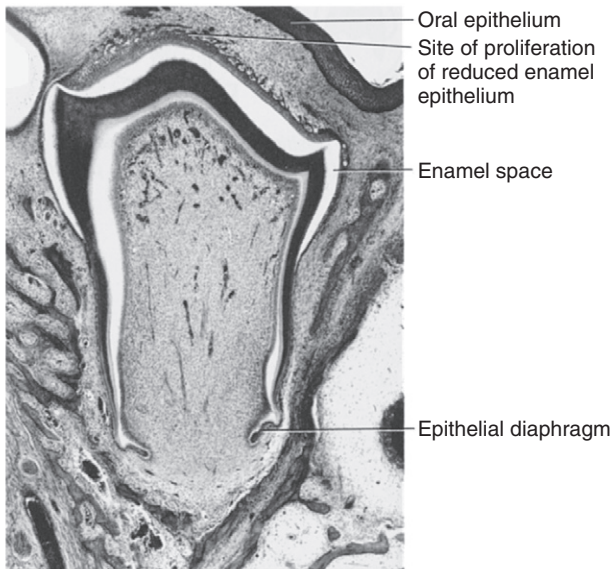


Fig. 6.4 Histology of the prefunctional eruptive phase. The root develops, and reduced epithelium overlying the crown approaches oral mucosa. Reduced enamel epithelium proliferates, anticipating fusion.

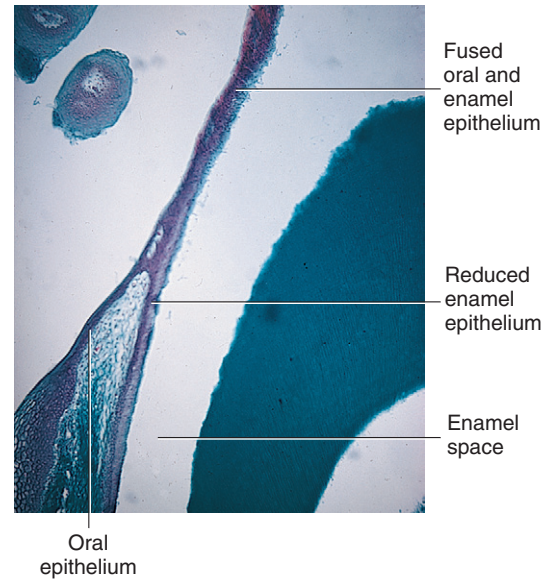


Fig. 6.6 Fused reduced enamel epithelium and oral epithelium overlie the enamel of crown. Enamel space occurs as enamel is dissolved in preparation of slide.

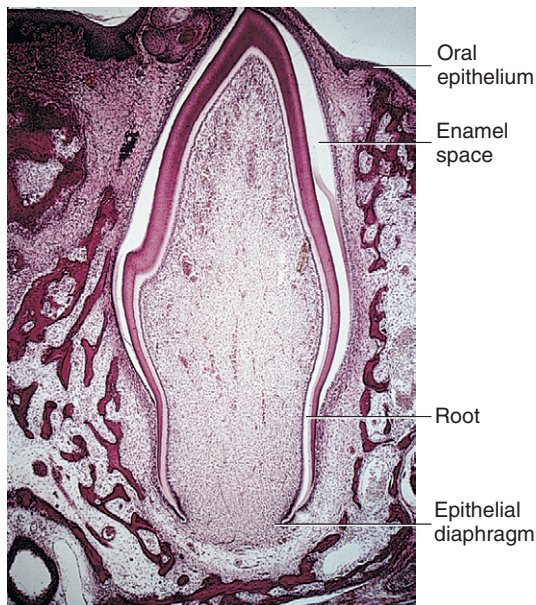


Fig. 6.5 Histology of an erupting cuspid tooth. The crown tip is in contact with oral epithelium.

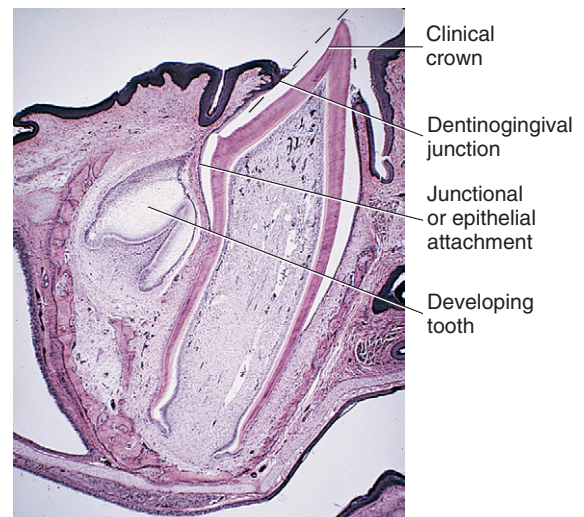


Fig. 6.7 An erupting primary tooth appears in the oral cavity. The permanent tooth's position is shown on the left. The dashed line indicates cuticle overlying the enamel surface of the erupting tooth.

3. **Penetration** of the tooth's crown tip through the fused epithelial layers allows entrance of the crown enamel into the oral cavity. Only the organic developmental cuticle (primary), secreted earlier by the ameloblasts, covers the enamel (**Fig. 6-7**).
4. **Intraoral occlusal** or **incisal movement** of the erupting tooth continues until clinical contact with the opposing crown occurs. The crown continues to move through the mucosa, causing gradual exposure of the crown surface, with an increasingly apical shift of the gingival attachment

(see **Fig. 6-7**). The exposed crown is the clinical crown, extending from the cusp tip to the area of the gingival attachment. In contrast, the anatomic crown is the entire crown, extending from the cusp tip to the cemento-enamel junction.

CLINICAL COMMENT

Hypereruption occurs with the loss of an opposing tooth. This condition allows the tooth or teeth to erupt farther than normal into the space provided.

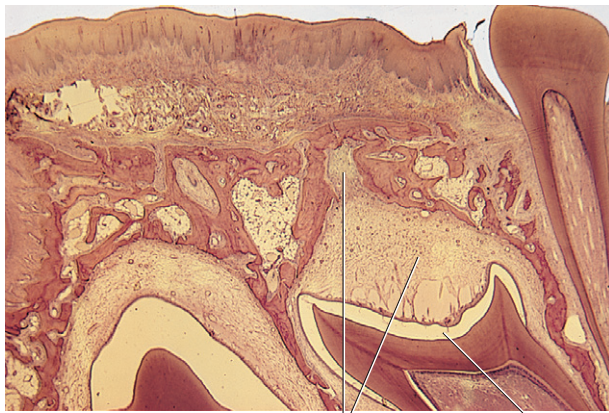


Fig. 6.8 Histology of a prefuctional erupting tooth. Observe the appearance of the eruption pathway developed overlying the crown.

Changes in Tissues

The prefuctional eruptive phase is characterized by significant changes in the **tissues overlying, surrounding, and underlying** the erupting teeth.

Overlying the Teeth

The dental follicle changes and forms a pathway for the erupting teeth. A zone of degenerating connective tissue fibers and cells immediately overlying the teeth appears first (**Figs. 6-8 and 6-9**). During the process, the blood vessels decrease in number, and nerve fibers break up into pieces and degenerate. The altered tissue area overlying the teeth becomes visible as an inverted triangular area known as the **eruption pathway**. In the periphery of this zone, the follicular fibers, regarded as the **gubernaculum dentis** or **gubernacular cord** (**Fig. 6-10**), are directed toward the mucosa. Some scientists believe that these fibers guide the teeth in their movements to ensure complete tooth eruption.

Macrophages appear in the eruption pathway tissue. These cells cause the release of hydrolytic enzymes that aid in the destruction of the cells and fibers in this area with the loss of blood vessels and nerves. Osteoclasts are found along the borders of the resorptive bone overlying the teeth. This bone loss adjacent to the teeth keeps pace with the eruptive movements of the teeth (see **Fig. 6-9**). **Osteoclasts** and **osteoblasts** constantly remodel the alveolar bone as the teeth enlarge and move forward in the direction of the growing face.

Although the process of eruption for permanent teeth is similar to that of the primary teeth, the presence of roots from primary teeth poses a problem. The resorption of their roots is similar to the process of bone resorption for the emergence of primary teeth. Permanent teeth establish an eruptive path lingual to the primary anterior teeth and the premolars under the primary molars. Permanent molars erupt into the alveolar free space behind primary teeth (see **Fig. 6-9**). Small foramina just posterior to the primary tooth row are evidence of the eruption sites of the anterior

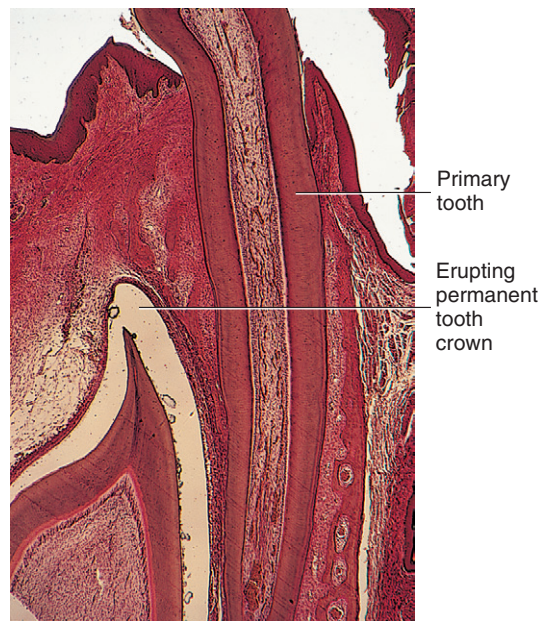


Fig. 6.9 Observe the relation of the functional primary tooth root on the right to the permanent prefuctional erupting crown on the left.

permanent teeth (**Fig. 6-11**). As the roots resorb, the primary crowns are lost or shed (**Fig. 6-12**). Dentin resorption is similar to bone resorption (see **Fig. 6-10**).

The resorptive process of primary and permanent teeth results from action of osteoclasts that arise from monocytes of the circulating bloodstream. These monocytes appear and fuse with others to form the multinucleated osteoclasts. Their function is to resorb the hard tissue. They do so by first separating the mineral from the collagen matrix through the action of the hydrolytic enzymes secreted by the osteoclasts. This enzymatic action is believed to occur within lacunae, which are developed by the osteoclasts. The osteoclast's cell membrane is in contact with the bone and becomes modified by an enfolding process termed the **ruffled border** (**Figs. 6-13 and 6-14**). This border greatly increases the surface area of the osteoclast and allows the cell to function maximally in bone resorption (**Fig. 6-15**).

Hard tissue resorption is believed to occur in two phases: the **extracellular phase**, in which the mineral is separated from the collagen and is broken into small fragments (see **Fig. 6-15**), and the **intracellular phase**, in which the osteoclast ingests these mineral fragments and continues the dissolution of this mineral. Crystals appear in cytoplasmic vacuoles of the osteoclast and are gradually digested within them. Resorption of mineral occurs at the ruffled border interface outside the cell, and the mineral is then taken within the cell (**Fig. 6-16**). Special **fibroblast** cells are believed to destroy the remaining collagen fibers secondarily by ingesting them in an intracellular phagolysosome system (**Fig. 6-17**). Amino acids resulting from this breakdown are used in the formation of collagen within this same cell and can be used in this same area for bone formation. Only the posterior permanent molars, which have no primary predecessor teeth, erupt through

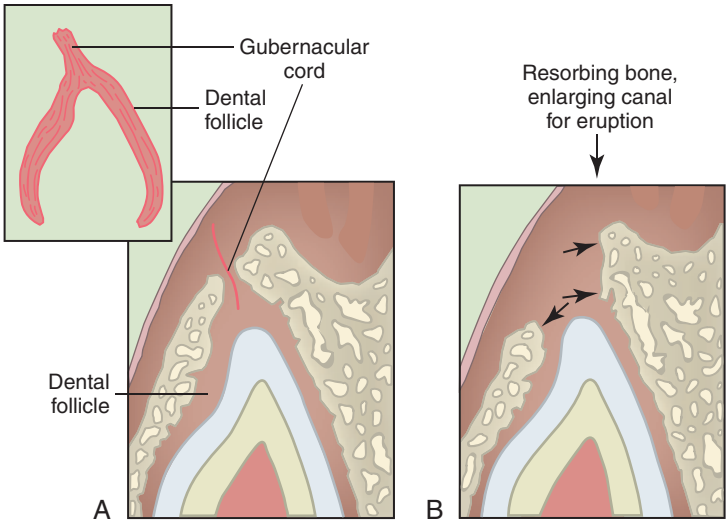


Fig. 6.10 Diagram of a developing eruption pathway. **A**, Early developing eruption pathway. **B**, Resorption of bone in eruption pathway.

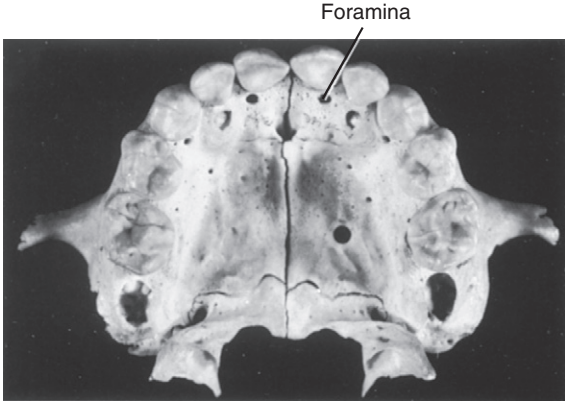


Fig. 6.11 Foramina palatal to maxillary primary incisors. These are sites of eruption for permanent incisors.

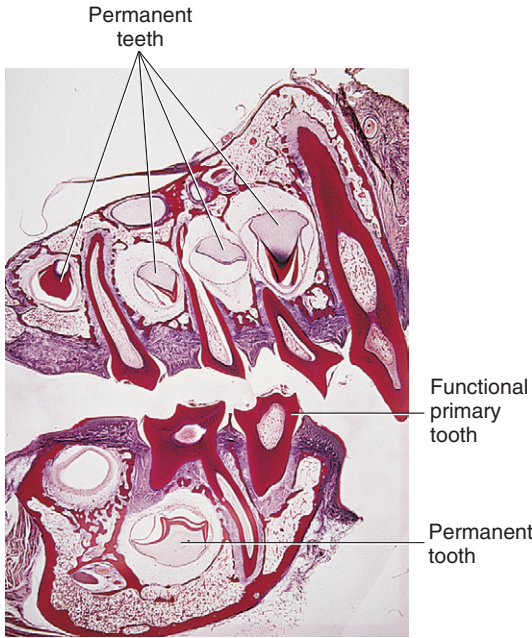


Fig. 6.12 Histology of maxilla in the mixed dentition period. Roots of erupted primary teeth are undergoing resorption. Crowns of developing permanent teeth appear below primary teeth.

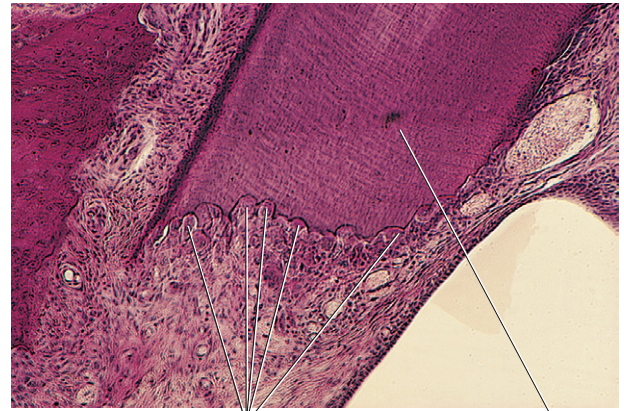


Fig. 6.13 Histology of active resorption sites on primary tooth roots. Osteoclasts appear in lacunae in root cementum and dentin.

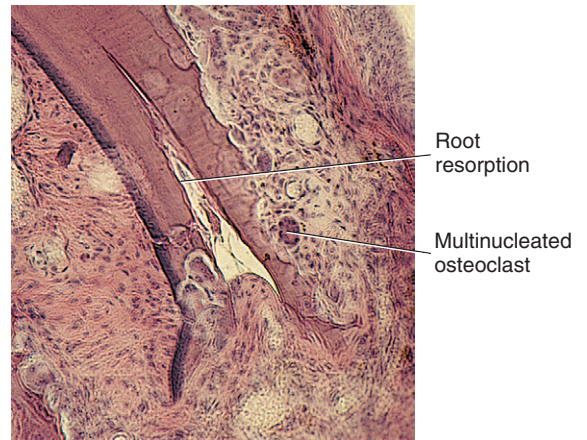


Fig. 6.14 Histology of osteoclasts in advancing resorption lacunae. Observe the large multinucleated cells shown within the lacunae.

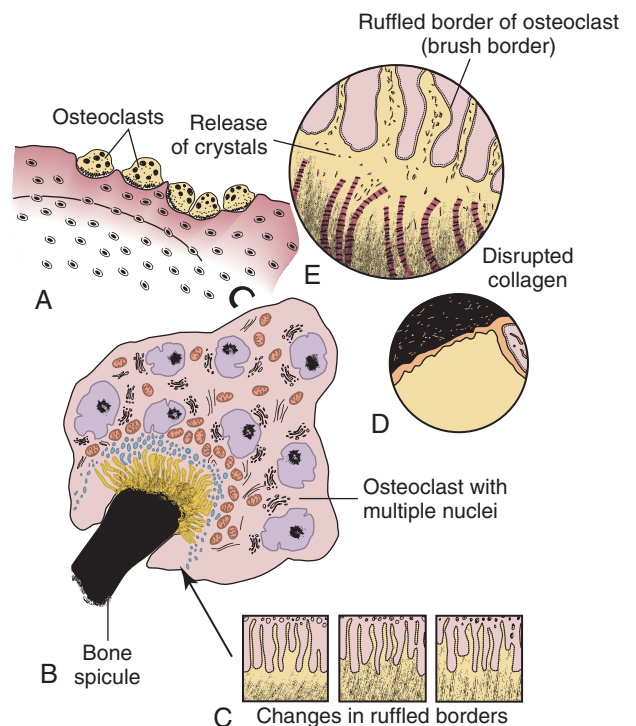


Fig. 6.15 Osteoclast activity. **A**, Osteoclasts in lacunae on bone surface. **B**, Large multinucleated osteoclasts with brush border in contact with bone spicule. **C**, High magnification of ruffled border of osteoclast showing mineral crystals passing into spaces between cell extensions. Unmasked collagen fibers are nearby. **D**, Clear zone on osteoclast surface. **E**, Ruffled border of osteoclast in constant motion or change.

Fig. 6.16 Diagram of ruffled border of an osteoclast. **A**, High magnification of unmasked collagen fibers. Mineral crystals are near the osteoclast surface. **B**, Diagram of uptake of crystals into osteoclast vacuoles.

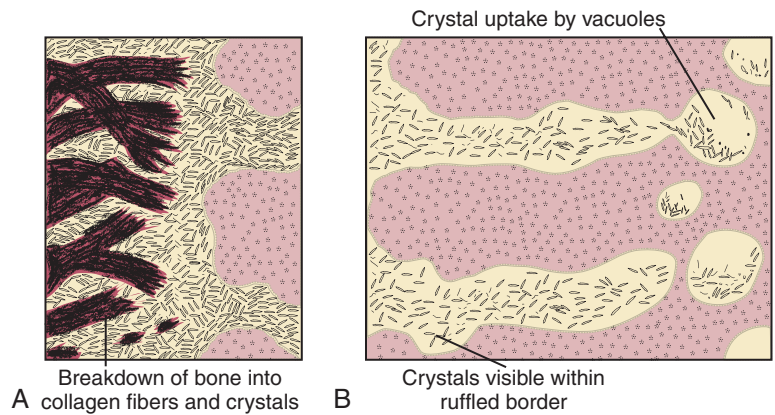


Fig. 6.17 Fibroblasts are capable of synthesis of collagen as well as its breakdown. Collagen fibers are phagocytosed into cells and are broken down to release amino acids (AA). These amino acids are then used to form new collagen molecules.

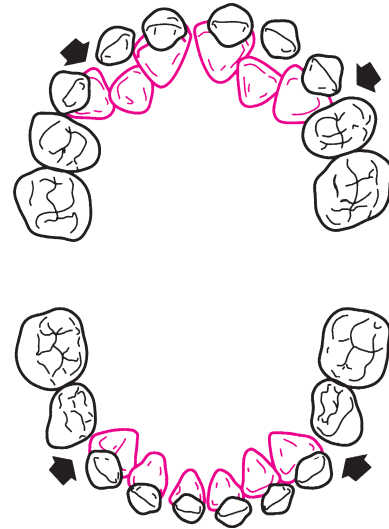
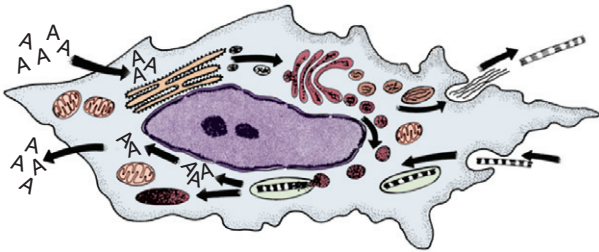


Fig. 6.18 The relationship between primary and permanent teeth during the mixed dentition period. (From Berkovitz BKB, Holland GR, Moxham BJ: Oral anatomy, histology, and embryology, ed 4, St. Louis, 2009, Mosby.)

alveolar bone (Fig. 6-18). Fig. 6-19 summarizes what happens in the tissues overlying the teeth during their prefunctional eruptive phase. Bone loss occurs as the tooth approaches the oral epithelium and forms an eruption pathway while the reduced enamel epithelium fuses with the oral ectoderm to form the junctional epithelium, which attaches to the developmental cuticle by hemidesmosomes formed by the gingival keratinocytes and helps prevent oral bacterial and other substances present in the oral cavity from entering the body (see Fig. 6-19, A). The tooth organ epithelium makes contact with the oral mucosa (see Fig. 6-19, B and C). This contact causes stretching and thinning of the oral membrane and finally its rupture and penetration by the tooth (see Fig. 6-19, D and E). Only a thin developmental cuticle then covers the tooth (see Fig. 6-19, E and F). As the tooth emerges farther into the mouth, more crown is exposed, and as clinical contact with the opposing tooth is made, the epithelial attachment shifts to the cervical area (see Fig. 6-19, G). Clinically, tooth eruption is seen as a blanching of the mucosa, and this condition may persist for several days because the eruptive process is neither rapid nor continuous. Each eruptive movement, however, results in greater exposure of the crown. With successive eruptive movements, the area of attached epithelium becomes lower on the clinical crown.

Surrounding the Teeth

The tissues around the teeth change from delicately fine fibers lying parallel to the surface of the tooth to bundles of fibers attached to the tooth surface and extending toward the periodontium. The first fibers to appear are those in the cervical area as root formation begins (Fig. 6-20, A). As the root elongates, bundles of fibers appear on the root surface (see Fig. 6-20, B and C). Fibroblasts are the active cells in both the formation and the degradation of the collagen fibers. With tooth eruption, the alveolar bone crypt increases in height to accommodate the forming root. After the teeth attain functional occlusion, the fibers gain their mature orientation (see Fig. 6-20, C). Special fibroblasts have been found in the periodontium around the erupting teeth. These fibroblasts have contractile properties. During eruption, collagen fiber formation and fiber turnover are rapid, occurring within 24 hours. This mechanism enables fibers to attach and release and

Fig. 6.19 Stages of tooth eruption. **A**, Tooth crown approaching oral epithelium in preeruptive stage. **B**, Contact of reduced enamel epithelium including the developmental cuticle fusing with oral epithelium. **C**, Fusion of reduced enamel epithelium including the developmental cuticle and oral epithelia. **D**, Thinning of fused epithelia. **E**, Rupture of oral epithelium, formation of the attached gingiva, and emergence. **F**, Clinical crown appearance into the oral cavity (pre-functional stage). **G**, Tooth erupting into functional occlusion.

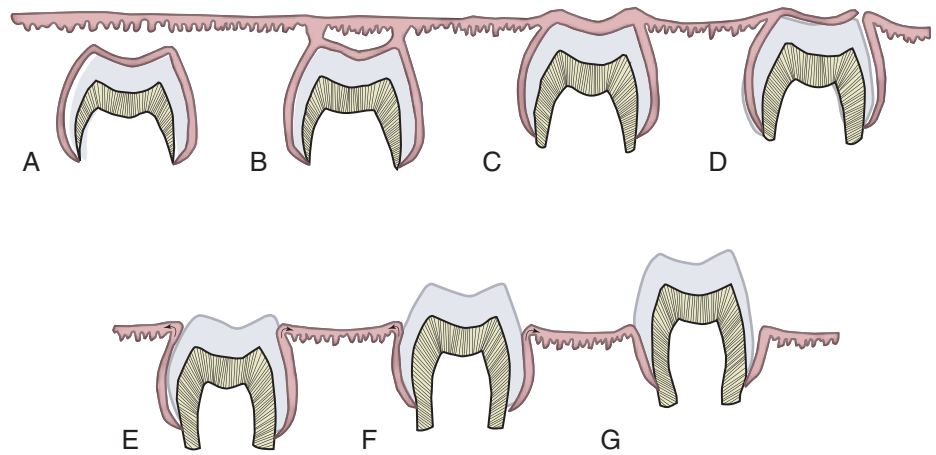
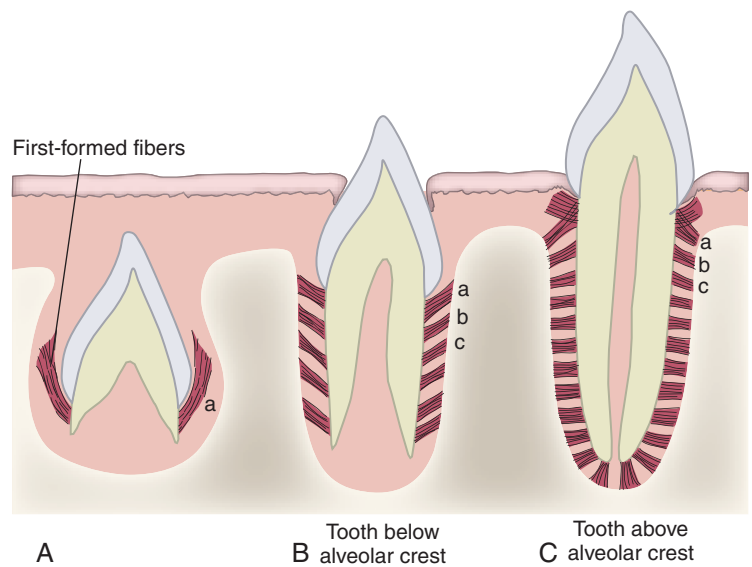


Fig. 6.20 Principal fiber development during tooth eruption. **A**, Origin of fibers at the cervical root area of crown. **B**, Fiber development with root growth. *a*, Initial fiber formation; *b*, development of secondary fibers; *c*, further fiber development. **C**, Change in orientation of the fibers with occlusal function. Initial fiber groups (*a*, *b*, and *c*) change direction with function.



attach in rapid succession. Some fibers may detach and reattach later while the tooth moves occlusally as new bone forms around it. Gradually the fibers organize and increase in number and density as the tooth erupts into the oral cavity. Blood vessels then become more dominant in the developing ligament and exert additional pressure on the erupting tooth (Fig. 6-21).

CLINICAL COMMENT

Teeth are considered submerged when eruption is prevented because of crowding or tipping of the adjacent teeth into the space created by the missing primary tooth. Retained primary teeth may be caused by the lack of development of the permanent successor.

Underlying the Teeth

As the crown of a tooth begins to erupt, it gradually moves occlusally, providing space underlying the tooth for the root to lengthen (Fig. 6-22). In the fundic region, these changes in the soft tissue and the bone surrounding the root apex are believed to be largely compensatory for the lengthening of the root. During root formation, the dentin of the root apex tapers to a fine edge that terminates in the epithelial diaphragm (Fig. 6-23). Fibroblasts form collagen around the root apex, and these fiber bundles become attached to the cementum as it begins to form on the apical dentin. Fibroblasts appear in great numbers in the fundic area, and some of these fibers form strands that mature into calcified trabeculae. These trabeculae form a network, or bony ladder, at the tooth apex. This is believed to fill the space left behind as the tooth begins eruptive movement (see Fig. 6-23). Gradually, this delicate bone ladder becomes denser as additional bony plates appear (Fig. 6-24). The